

What if a surgically removed neck lymph node turns out to be cancer?

A rising epidemic in the United States is throat cancer, specifically a tumor called squamous cell carcinoma, induced by the human papilloma virus (HPV). Approximately 12,000 cases occur each year and the number is increasing. In this disease, small cancers in the throat spread quickly to the lymph nodes in the neck. In fact, an enlarged lymph node in the neck is often the first overt sign of this disease. The standard treatment in such a situation is to use a fine needle to gather some cells from that neck mass for diagnosis. However, it is not uncommon that a general surgeon or ear, nose, throat doctor in the community may surgically remove an enlarged neck lymph node from a patient, a procedure called an open biopsy, only to find out later that the diagnosis is HPV-induced throat cancer. The main concern with surgical removal of such a lymph node is the potential to spread the cancer in the neck during the procedure. This type of cancer is commonly treated with surgery, but when the diagnosis is known ahead of time, a comprehensive and careful removal of the major neck lymph nodes is performed, which is a distinctly different type of operation than open biopsy of a single enlarged node. A major question, then, is the impact of an open biopsy of a single enlarged cancerous lymph node on the overall prognosis of the patient when the tumor is HPV-induced squamous cell carcinoma.

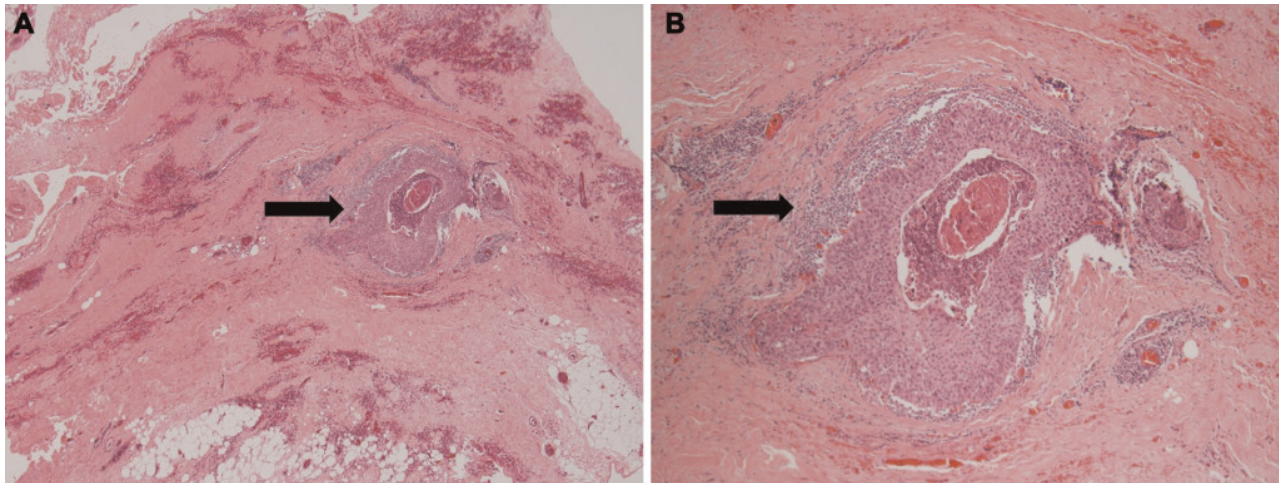


Fig. 1. Hematoxylin and eosin–stained slides of the open biopsy scar excised during completion neck dissection. An island of tumor (arrow) is seen within the fibrous stroma of the scar under 403 (A) and 1003 (B) magnification.

To address this question, we studied 45 such patients, who had an open biopsy of an enlarged lymph node which later turned out to be HPV-induced squamous cell carcinoma. All these patients were subsequently treated with surgical removal their throat cancer, a comprehensive removal of

the major neck lymph nodes and the scar from their prior open biopsy site, along with radiation therapy when appropriate. We compared this group to 90 patients with similar disease stage and medical histories who did not have an open biopsy procedure but who were treated with similar definitive surgical therapy and radiation treatment. We found that complications, disease recurrence, an overall survival were similar between groups. In fact, 5-year overall survival was nearly 100% in both groups. In addition, we identified cancer within the excised surgical scar from the prior open biopsy site in 7% of patients (Figure 1). In that way, we do not advocate open biopsy for diagnosis of an enlarged neck lymph node, since it may spread cancer into the surgical scar in the neck. However, if an open biopsy is performed, and the patient is subsequently treated with definitive surgery and radiation therapy as needed, outcomes are excellent and no different than if the patient had not undergone the open biopsy procedure in the first place.

Joseph Zenga, MD and Jason T Rich, MD

Washington University School of Medicine

Department of Otolaryngology-Head and Neck Surgery, USA

Publication

[Definitive Surgical Therapy after Open Neck Biopsy for HPV-Related Oropharyngeal Cancer.](#)

Zenga J, Graboyes EM, Haughey BH, Paniello RC1, Mehrad M, Lewis JS Jr, Thorstad WL, Nussenbaum B, Rich JT.

Otolaryngol Head Neck Surg. 2016 Apr