Atlas of Science
another view on science
http://atlasofscience.org

Automated chest X-ray screening: can edge map measure the evidence of pulmonary abnormalities?

Among many pulmonary diseases, according to the 2014 WHO report, Tuberculosis (TB) is considered as one of the deadliest communicable diseases. While TB cure rates over 90% have been documented in resource-rich countries, its detection and treatment remains a major challenge. An estimated 9 million new cases are detected each year, particularly in Sub-Saharan Africa. TB is an infectious disease caused by the bacillus Mycobacterium tuberculosis, and the lungs are typically affected, however it may also infect other organs. TB is highly contagious, and therefore early detection and treatment is the key to reduce the further burden of disease. Chest X-ray (CXR) has always been a widely used test to detect pulmonary abnormalities (TB, for instance). In 2006, the WHO revisited the usefulness of chest radiography mainly because of the rise of smear negative TB, and also because digital chest radiography has made x-ray much cheaper and easier to use. Using digital CXRs, an abnormality suspect can be screened. But, a major problem remains: human experts need to interpret these CXR images. Therefore, a computer aided screening system could help population screening in the field, particularly in regions with few radiologists, in recommending high risk patients for appropriate treatment.

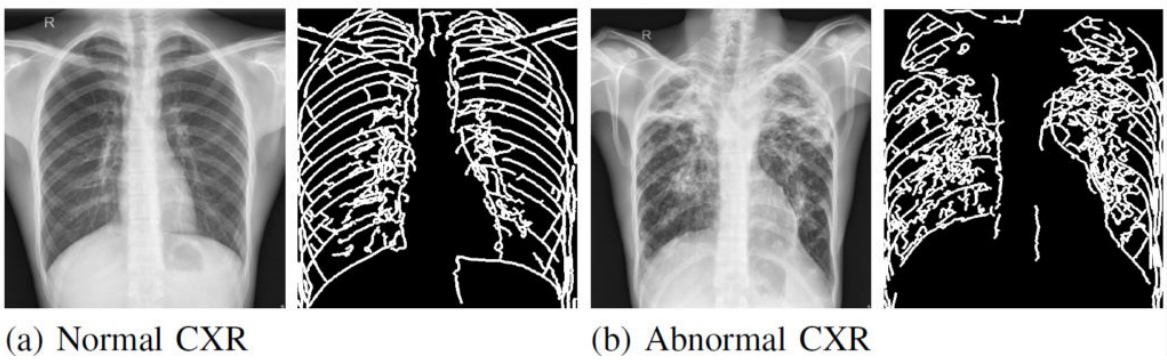

Fig. 1. Edge maps from two different chest X-rays: (a) normal and (b) abnormal.

Studies over four decades suggest that no computer-aided diagnosis systems can accurately read the CXRs because it requires accurate and reliable detection of lung boundaries, nodules and cavitations; suppression of ribs and clavicles; and recognition of other radiological presentations. Errors in these steps degrade the performance of subsequent feature-based classifiers, and also increase the computational complexity.

Therefore, state-of-the-art methods suffer from both accuracy and processing time. Keeping these latter terms in mind, our method can be highlighted as follows:

- As shown in Fig. 1, differences due to abnormalities in CXRs can often be detected in the form of corrupted and/or deformed thoracic edge maps. Literally, note that the number of edge pixels in a fixed-size region tells us how busy that region is, and more importantly the directions of the edges also help characterize the texture. To interpret edges, we have computed pyramid histogram of

orientation gradients (PHOG) as shown in Fig. 2, since since it has a capacity of exploiting spatial distribution of edges locally (i.e., the local shape is captured by the distribution of edge orientations within a region, and spatial layout by tiling the image into regions at multiple resolutions). Therefore, like the state-of-the-art methods, it does not require to use additional shape and texture-based features, and it does not require precise lung segmentation.

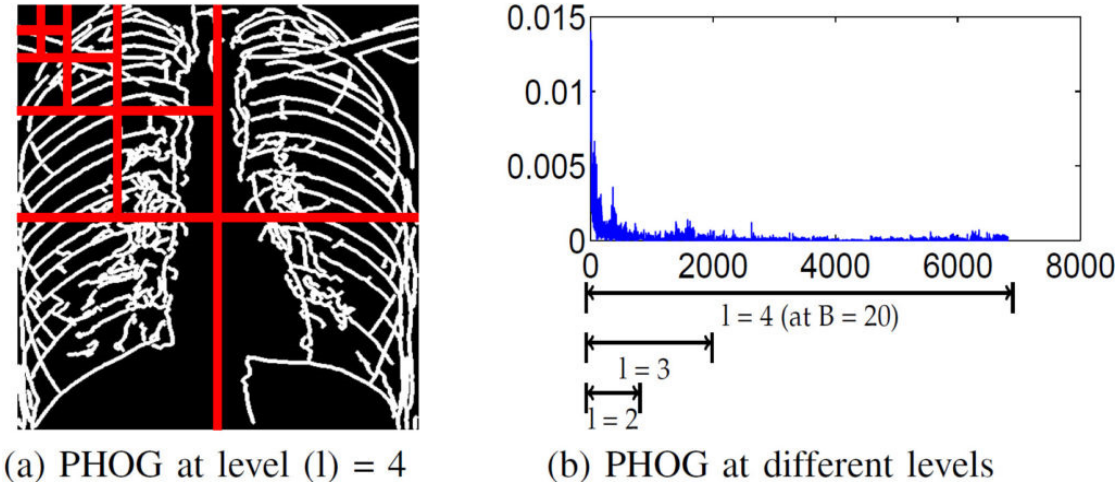

Fig. 2. Histogram of orientation gradients (HOG) feature vector representation at different pyramid levels, $l \leq 4$, for bins, $b = 20$.

- From two CXR benchmark collections made available by the U.S. National Library of Medicine, we have achieved (through the use of neural network classifier) a maximum abnormality detection accuracy of 86.36% and area under the ROC curve of 0.93 at one second per image, on average. The method outperforms the previously reported state-of-the-art results (Jaeger et al., 2014 and Karagyris et al., 2016). More importantly, our method is approximately 25 times faster than the recent state-of-the-art methods mentioned earlier. This shows the interest in mass screening. Therefore, to be considered in Kenya, South Africa (Project at the US National Library of Medicine), where computational resources are limited, our system is appropriate and justified.

In conclusion, we have proved that edge map can measure the evidence of pulmonary abnormalities and is able to provide better performance than the reported state-of-the art methods.

K.C. Santosh[1], ***Szilárd Vajda***[2]
[1]*Dept. of Computer Science, The University of South Dakota, SD, USA*
[2]*Dept. of Computer Science, Central Washington University, WA, USA*

Publication

Edge map analysis in chest X-rays for automatic pulmonary abnormality screening.
Santosh KC, Vajda S, Antani S, Thoma GR
Int J Comput Assist Radiol Surg. 2016 Mar 19