

Diagnosis and management of bile leaks after hepatectomy

One of the most common complications of hepatic resection is biliary leak, which may happen from the cut-surface of the liver that is made by the surgeon during the operation. Biliary leak may be an important source of morbidity and mortality being sometime responsible for infection and sepsis. Its diagnosis and management are therefore of utmost importance in liver surgery, but unfortunately there is no agreement among specialists on the definition of post-resection biliary leak.

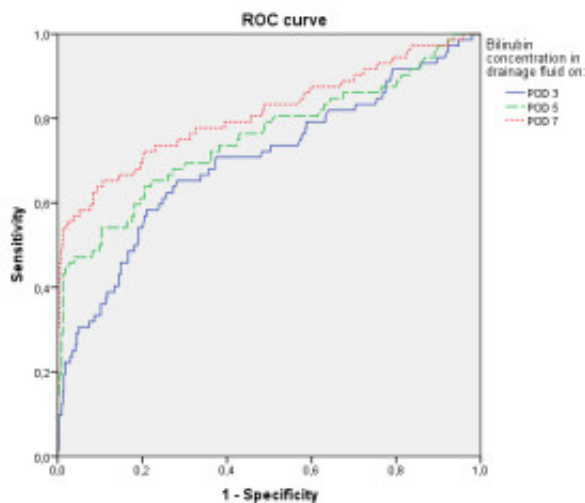


Fig. 1. The ROC analyses for the timing of drain removal. The figure shows that the AUC value on POD7 (AUC=0.813; P less than 0.001) had the greatest accuracy for predicting bile leaks compared with that on POD5 (AUC = 0.754; P less than 0.001) and POD3 (AUC=0.700; P less than 0.001).

We recently conducted a study with the aim to validate our definition and management of biliary leaks after hepatic resection comparing also our results with those proposed by other authors. In this study we prospectively collected 475 patients operated from 2004 to 2012 at the Department of Hepatobiliary & General Surgery of the Humanitas Research Hospital IRCCS in Milan, Italy. In these patients the surgical drains were maintained for 7 days, and the bilirubin was measured on postoperative days (PODs) 3, 5, and 7. Based on previous studies, the drains were removed if the bilirubin on POD 7 was less than that on POD 5 and less than 171 $\mu\text{mol/l}$ (10 mg/dl). We also conducted statistical analyses on prognostic factors for biliary leaks.

Interestingly, among 475 consecutive patients, 39 (8 %) had biliary leaks, but only 8 (1.7 %) required postoperative interventions. In comparison with other studies, we observed a higher rate of bile leaks, but at the same time, we observed a lower rate of interventional procedures. Indeed,

other authors that did not use surgical drains or use those drains up to 2 or 3 days only reported postoperative radiological interventions up to 19% of the patients with higher operative mortality (7.9%). Conversely, we recorded a 30-day mortality rate of 0.4% and, as said, only 1.7% of postoperative radiological interventions. Moreover, based on the area under the receiver operating characteristic curve the highest predictive value for the detection of biliary leaks was exactly on POD7 (0.81; P less than 0.001) (Fig. 1.), showing then that the surgical drains should left in place up to 7 days.

Intriguing, we tested several different prognostic factors for the development of biliary leaks but only the liver pedicle clamping lasting >90 min (OR = 3.4; P less than 0.001), the performance of extended resections (OR = 6.4; P = 0.007), the use of blood transfusions (OR = 2.4; P = 0.035), and the performance of resections including segment I (OR = 1.9; P = 0.033) or segment V (OR = 1.8; P = 0.024) were independently associated with an increased risk of bile leak (Fig. 2.).

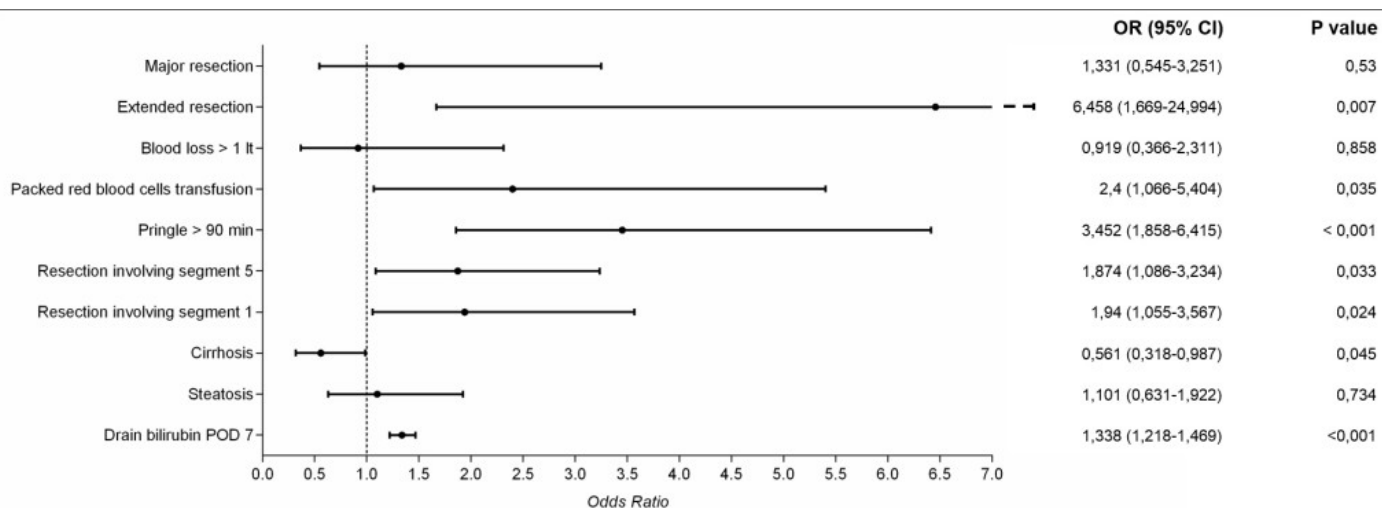


Fig. 2. Odds-ratio plot of the multivariate analysis. This figure gives an overall perspective of the different risk factors for bile leaks.

In conclusion, the proposed definition of biliary leak provides effective recognition of those that are clinically relevant, leading to their proper management with a drastic reduction of the risk of unrecognized collections, with or without negligible drain-related risk. The greater the complexity of hepatic resection, the greater the risks of biliary leak, which may be effectively managed with long-term drain maintenance in most patients.

Publication

[Diagnosis and Management of Bile Leaks After Hepatectomy: Results of a Prospective Analysis of 475 Hepatectomies.](#)

Donadon M, Costa G, Cimino M, Procopio F, Del Fabbro D, Palmisano A, Torzilli G.

World J Surg. 2015 Jul 7