

EEG reactivity in coma

The electroencephalogram (EEG) is a test of brain activity applied on Hospital Intensive Care Units (ICUs) to detect seizure activity, with up to half of ICU patients having seizures associated with their neurological condition. For this reason, EEG is recommended for patients with unexplained altered consciousness and to aid the neurological prognosis of comatose patients following out of hospital cardiac arrest (OOHCA).

EEG involves recording the brain activity at rest and testing EEG reactivity (EEG-R) to external stimuli. This EEG phenomenon relies upon the integrity of the associated sensory receptors and afferent neural pathway to the brainstem, and relay in the thalamus to the cortex. But what makes an EEG reactive? Neurophysiologists informally define EEG-R as a reproducible change in amplitude or frequency of waveforms, following a given stimulus. For example, in the awake, mature and “healthy” brain, visual stimulation (eye opening) causes attenuation of the posterior-dominant alpha rhythm (activity between $8 < 13$ Hz); see Figure 1. On ICU, testing of EEG-R forms part of international guidelines for continuous EEG. However, scrutiny of the use of this term suggests that defining EEG-R and testing protocols lack standardisation, particularly in the context of prognostication of comatose patients.

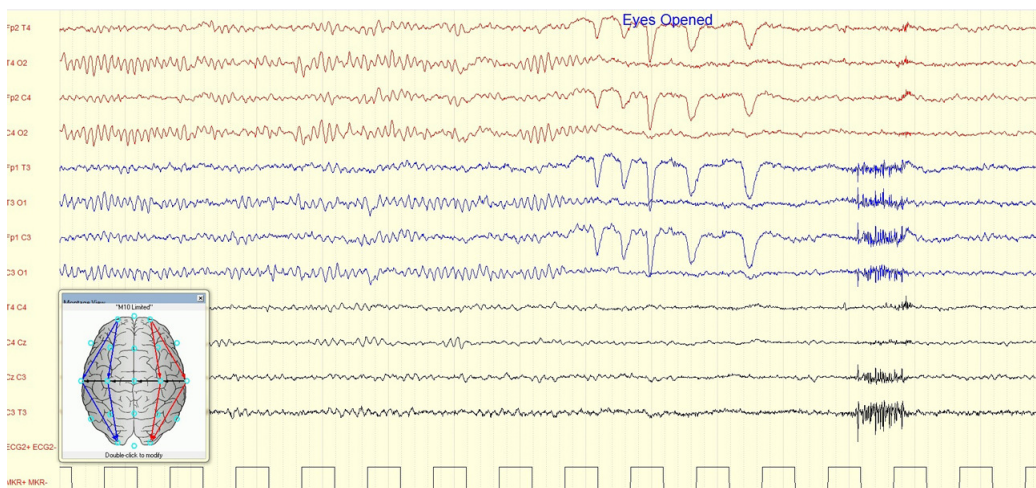


Fig. 1. Example of alpha activity in the EEG during eye closure, and attenuation of alpha activity with eyes open.

So firstly, why should we test EEG-R in comatose patients? Patients admitted to ICU following OOHCA with return of spontaneous circulation often have associated hypoxic-ischaemic brain injury; the clinical outcome ranges from death to full neurological recovery, but cognitive impairment is frequent in survivors. EEG-R (tested at ≥ 48 hours post-OOHCA) has been identified as a predictor of neurological outcome, suggesting whether the afferent neural pathway is intact. There is consensus that the presence of EEG-R in patients with aetiology of OOHCA suggests better neurological prognosis (ie. recovery of consciousness and cognitive function) and that absent EEG-R is *usually* associated with a poorer neurological outcome (ie. death or vegetative state). This information should be identified promptly, considering patient dignity and relatives' concern.

However, of particular importance is that EEG-R and neuro-prognosis are not exclusively binary. Sedation can alter the background EEG and may affect EEG-R; a recent study found a minority of patients had absent EEG-R followed by favourable outcome, where sedation or the time point of testing may have confounded EEG-R. Therefore, standardisation of testing conditions and its timing may aid interpretation of EEG-R, and should be used in conjunction with other appropriate neuro-prognostic tests.

Furthermore, we face the dilemma of what precisely defines EEG-R in a comatose patient. In 2018, a panel of experts on EEG in ICU patients admitted with OOHCA produced an international consensus definition for EEG-R: a reproducible change in EEG waveform in response to standardised stimuli, excluding seizure induction or artefacts due to muscle, movement or eye blink; see example in Figure 2. This aids EEG interpretation, but the *standardised stimuli* remain heterogeneous. Stimulation methods, duration and frequency vary, although most centres apply visual, auditory and various noxious stimuli. Noxious stimuli generally produce greater EEG changes, but some modes of noxious stimulation rely on peripheral perception, which may vary between patients.

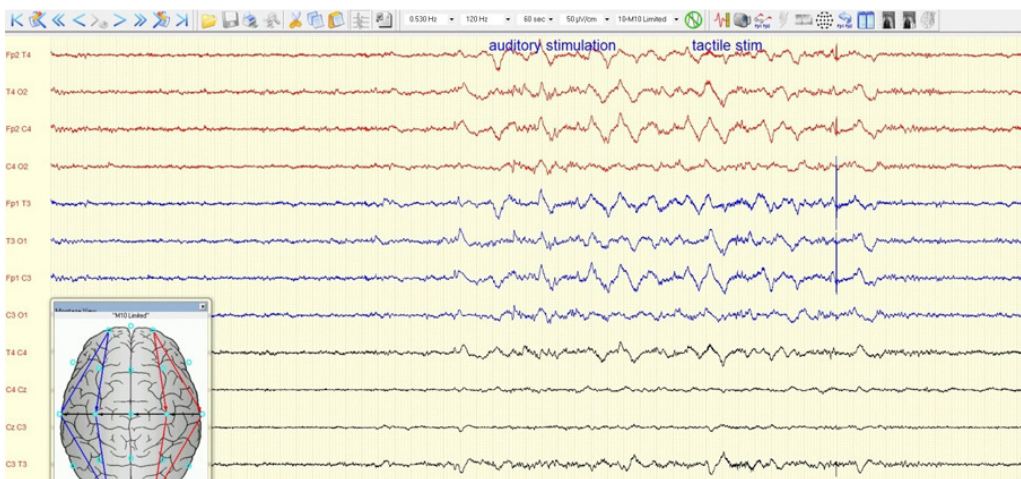


Fig. 2. Example of EEG changes seen with auditory and tactile stimulation.

Whilst EEG-R clearly has a valuable role in the neurological prognosis of comatose patients, standardisation of EEG-R protocols is essential to creating a universal understanding of its meaning and implications in the ICU setting.

Lealah F Nouri, Nick Kane
North Bristol NHS Trust, United Kingdom

Publication

[EEG-reactivity: What is it good for?](#)

Nick Kane, Samantha Taylor

Resuscitation. 2019 Sep