

## Lung cancer imaging before surgery and the role of brain MRI

Lung cancer kills more people each year than any other cancer worldwide. The best chance at curing the cancer is with surgery, however not all lung cancers can be taken out. Surgeons use a variety of imaging techniques to see if a cancer can be removed. They also check the rest of the body to see if the cancer has spread. If it has, surgery is no longer an option. There are three main scans that are important in looking at lung cancers – a CT scan of the chest, a PET/CT scan of the whole body, and an MRI scan of the brain. Using the results from these tests, the surgeons can guess how advanced a cancer is. This is known as the clinical stage. If the cancer is taken out, they can confirm how advanced it is. This is known as the pathological stage. In this study, we wanted to compare how well the clinical stage, based on the three imaging techniques, matches with the pathological stage after surgery. We also wanted to know if these patients need to have a brain scan before surgery, and how much it costs to perform all these tests.

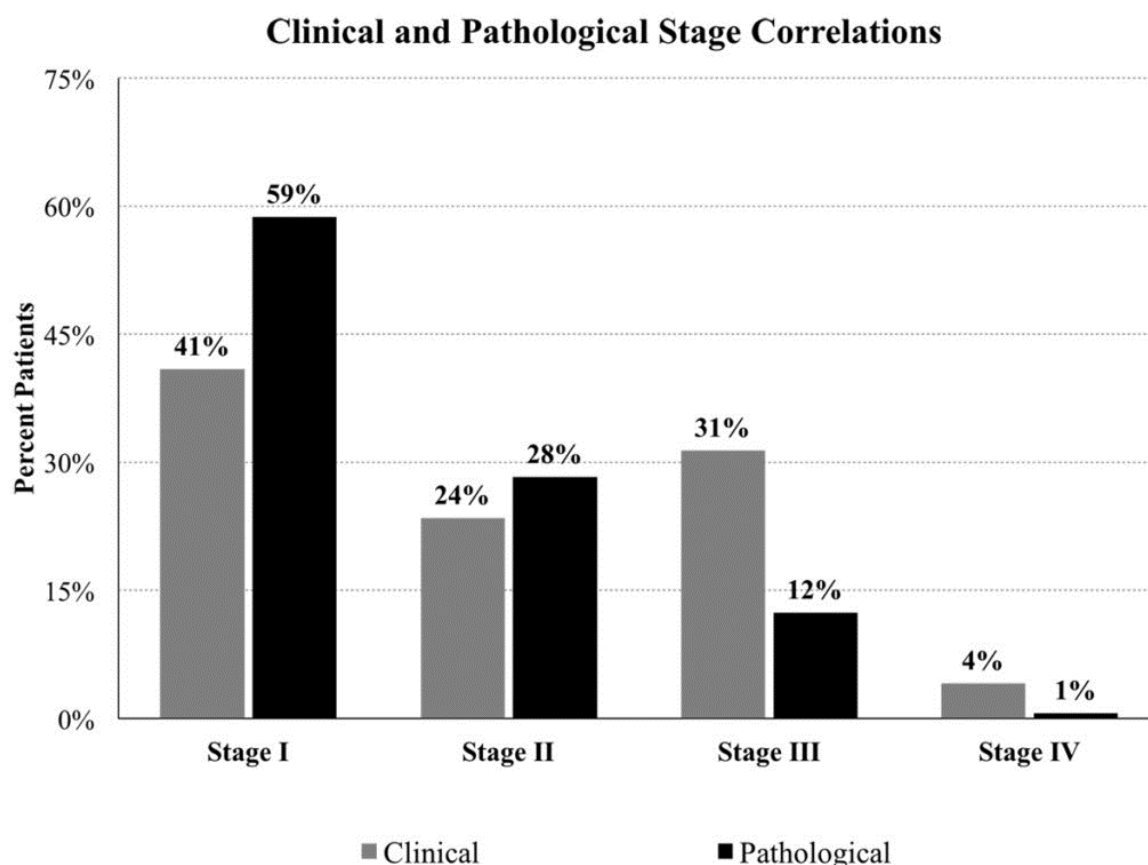


Fig. 1. A comparison of how many patients were in each stage based on the clinical imaging tests, and the pathology after surgery. Stage I is the least advanced, and stage IV is the most advanced.

To answer these questions, we gathered information about patients who had lung cancer surgery between January 2012 and June 2014 at our hospital. We compared the clinical and pathological stages of the lung

cancers to determine the accuracy the imaging tests. We also counted the number of people who had cancer spread to the brain before and after surgery. Finally, we collected the costs of doing each test.

We included 315 patients in the study and all of them had primary lung cancer, meaning that the cancer was originally from the lung. We calculated a diagnostic impact of 95.3%. This means that 95.3% of patients were treated appropriately based on the clinical stage assigned before surgery. Even though the clinical stage only matched the pathological stage 50.2% of the time, it was more important to see that patients were still getting the right treatment. During the brain scan before surgery, we found 4 patients that had cancer spread to the brain. After surgery, an additional 6 patients had a spread of cancer to the brain. In total, 3.5% of all the patients had brain disease during the study. Since this is a very small proportion, we determined that it may be worthwhile to do more research on the usefulness of the brain scan before surgery. Finally, we determined that the cost of doing all the imaging tests in this population was \$367,292. If we did not do the brain scan this would be decrease to \$250,020, representing a savings of 31.9%.

In looking at other research on this topic, we found that there were no other studies looking at using the combined results of imaging tests to determine clinical stage. However, the imaging tests have been studied independently, so this research is a good next step towards more accurate staging. Other studies have looked at the use of brain scans before lung cancer surgery. Although there is some disagreement, it seems that in general a brain scan is only recommended for more advanced cases of lung cancer, and may not be helpful in early cases before surgery.

In conclusion, the use of combined imaging tests before lung cancer surgery is accurate only half the time, but almost always ensures that patients receive the right treatment. Further research is needed to evaluate the usefulness of a brain MRI before surgery. If this test was no longer performed, there is potential for significant cost savings.

***Jordyn Vernon, Waël C. Hanna***

*Division of Thoracic Surgery, McMaster University, Hamilton, Ontario, Canada*

## **Publication**

### [Comprehensive Clinical Staging for Resectable Lung Cancer: Clinicopathological Correlations and the Role of Brain MRI.](#)

Vernon J, Andruszkiewicz N, Schneider L, Schieman C, Finley CJ, Shargall Y, Fahim C, Farrokhyar F, Hanna WC

*J Thorac Oncol. 2016 Nov*