

## Newly discovered brachial plexus variation may explain cases of undiagnosed Thoracic Outlet Syndrome

The brachial plexus is the network of nerves that carries sensation from the skin of the upper extremity (arm), and supplies the muscles of the shoulder, arm, forearm, and hand. These nerves originate from the spinal cord, and travel through the neck where they interdigitate with each other and exchange fibers, before traveling out into the arm. In the neck, they pass several points of constriction where they can become impinged, causing a condition called Thoracic Outlet Syndrome (TOS). TOS affects 1-8% of the U.S. population, and results in pain, numbness, tingling, or even muscle weakness radiating along the nerve pathways down into the arm, forearm and/or hand. TOS is usually diagnosed by assessing the strength of the pulse of the subclavian artery, which travels with the nerve branches of the brachial plexus, to assess whether the artery is also impinged. These standard diagnostic tests for TOS presume that the artery and nerves are compressed together, often as they pass between two muscles of the neck, the anterior and middle scalene muscles. However, in reality many patients present to the clinic with TOS-like symptoms but are unable to obtain an official TOS diagnosis, due to lack of change in arterial pulse. Here, we describe previously unrecognized variation in brachial plexus anatomy that may cause TOS symptoms, while rendering traditional diagnostic TOS tests and treatments insufficient.

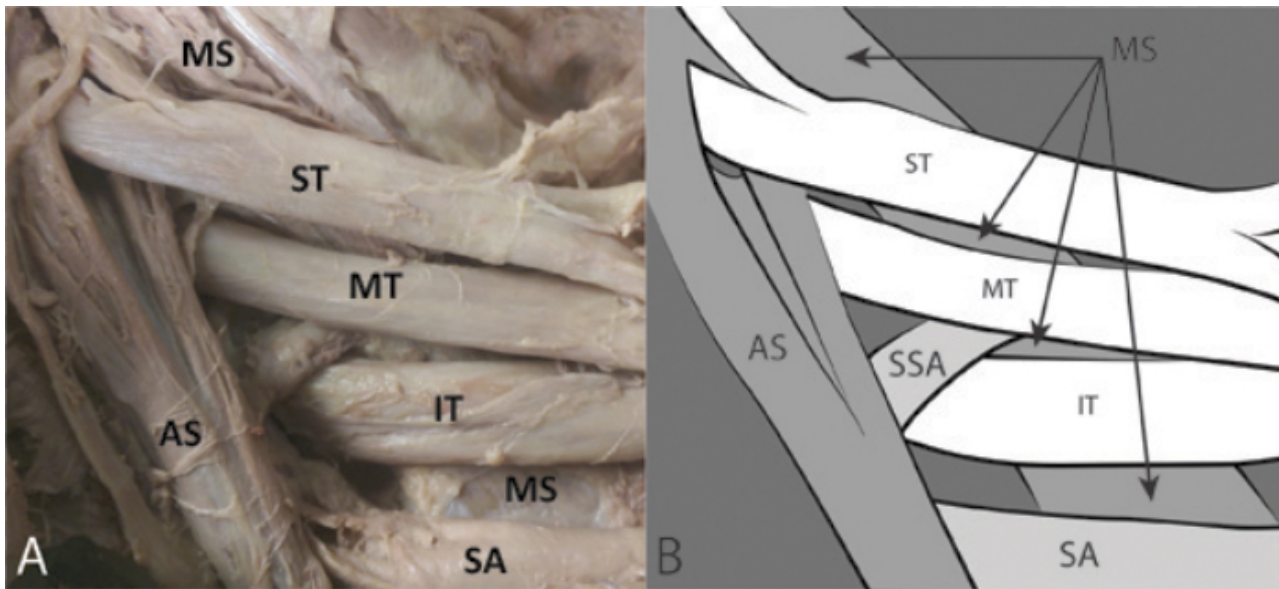


Fig. 1. Newly discovered variation in which the superior trunk of the brachial plexus pierces the anterior scalene muscle (found in 45% of our sample). This condition may cause impingement of the nerves resulting in Thoracic Outlet Syndrome (TOS), in which pain, numbness, tingling, and/or muscle weakness may radiate down the arm. AS= Anterior scalene muscle; IT= Inferior trunk of brachial plexus; MS= Middle scalene muscle; MT= Middle trunk of brachial plexus; SA= Subclavian artery; SSA= Suprascapular artery; ST= Superior trunk of brachial plexus. Figure by Brent Adrian.

Our team dissected the necks of 65 human cadavers, traced out the paths of the brachial plexus nerve branches, and documented the relationships between the nerves, arteries, and muscles of the neck. In 45% of our sample, we found previously undescribed variations in which parts of the brachial plexus travel through the muscle belly of the anterior scalene (Fig. 1). These patients would likely have a predisposition for the muscle to impinge upon the nerves resulting in TOS symptoms, while the subclavian artery, traveling in its normal position between the muscles, would be unaffected. This situation would result in a normal pulse and consequently a negative TOS diagnostic test, despite neurogenic symptoms. This anatomical variation, therefore, may be one cause of the large number of currently undiagnosed TOS cases.

These findings indicate that traditional diagnostic tests for TOS may be inadequate for identifying certain types of TOS, and suggest that additional diagnostic methods, such as ultrasound, may be useful. It is also important that clinicians are aware of these common brachial plexus variants, because they can affect the efficiency of traditional TOS treatment. For example, some current types of TOS treatment would actually exacerbate TOS symptoms in a patient with one of these anatomical variants, rather than offering relief, and should be avoided in these patients. Our team is currently expanding our research on this topic by conducting ultrasounds on the necks of a sample of patients with TOS symptoms to determine what percentage of them have one of these brachial plexus piercing variants, which could explain their symptoms. We are also assessing the efficacy of ultrasound as a new TOS diagnostic tool to be used in conjunction with traditional diagnostic testing.

**Heather F. Smith**

*Department of Anatomy, Arizona College of Osteopathic Medicine  
and College of Veterinary Medicine, Midwestern University, USA*

## **Publication**

[Anatomical variations in the brachial plexus roots: implications for diagnosis of neurogenic thoracic outlet syndrome.](#)

Leonhard V, Smith R, Caldwell G, Smith HF  
*Ann Anat.* 2016 Jul