

Palliative treatment of superior vena cava syndrome with use of stent

Superior vena cava (SVC) syndrome is a clinical diagnosis that is caused by compromised venous blood return from the head and upper extremities due to compression and obstruction of the SVC. Respiratory distress, dysphagia, swelling of the head and upper body are main symptoms, but neurologic symptoms can also occur. Intra thoracic malignancy and venous access catheters are the most common causes of SVC syndrome. In malignancies the SVC obstruction is caused by compression or direct invasion of the neoplasm or by lymph node invasion of the mediastinum. Palliative treatment of SVC syndrome with stents is a well-accepted treatment in the terminal phase of malignant thoracic disease. This endovascular treatment is safe and effective with rapid relief of symptoms and has become the first-line treatment in recent years. A new nitinol stent has been designed specifically for venous stenting, and the aim of the present study was to evaluate the technical and clinical outcome of stenting the SVC in patients with terminal cancer and manifest clinical SVC syndrome.

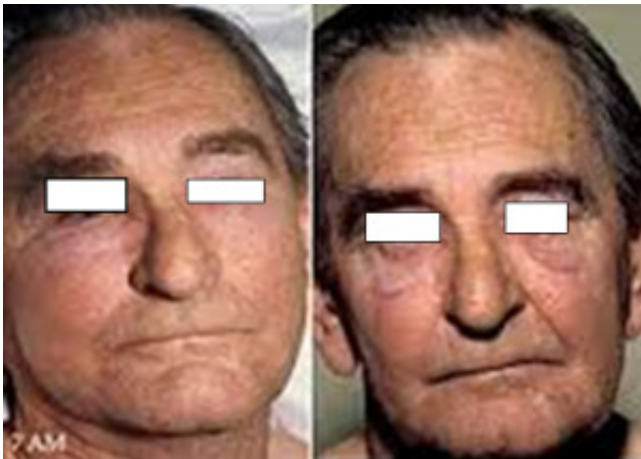

Fig. 1. Superior vena cava syndrome with swelling of the head before (to the left) and after treatment with stent (to the right).

All patients in the present study presented with clinical SVC syndrome and the diagnosis of compromised SVC run-off was verified by computed tomography (CT). All patients had advanced cancer in the right lung and/or spread to mediastinal lymph nodes and/or invasive disease into the mediastinum. The patients were in terminal stage without further possibility of curative treatment and had received maximal adjunct chemo- and radiotherapy

The stent procedure is minimally invasive and performed under local analgesia usually through the right femoral vein. Under fluoroscopy guidance, the stenotic lesions are crossed and the stents

deployed covering the stenosis and afterwards dilated with a balloon.

Patients were followed-up by their referring clinicians and had repeated contrast-enhanced CT 1-3 months after stent implantation or in case of recurrence of SVC symptoms. Good clinical effect was defined as complete relief of symptoms ascribed to SVC syndrome and patients' satisfaction with the result. Recurrence of SVC syndrome was recorded. The primary end-point of the study was clinical effect 48 hours after stent treatment, and secondary end-points were SVC syndrome recurrence-free survival and stent occlusion.

The technical success was 75% with stents deployed in the intended position, without associated complications and with a good clinical result was achieved in 92% of the patients. The patients were followed until dead with frequent clinical examinations and contrast enhanced CT, or in case of symptom progression. The two patients with stent occlusions did not have recurrence of SVC syndrome requiring re-intervention.

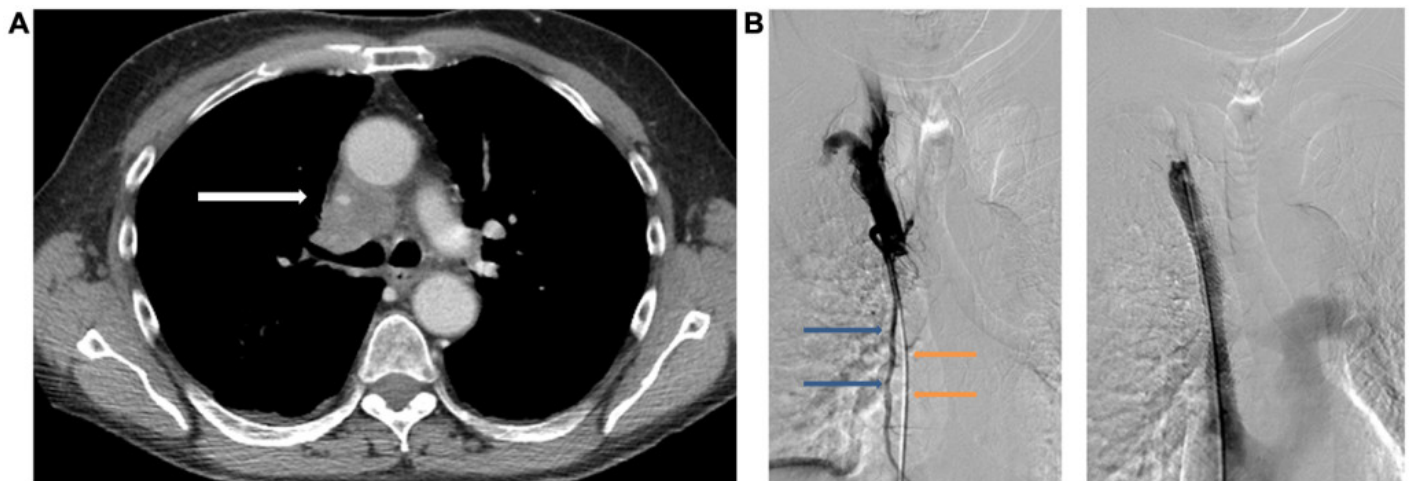


Fig. 2. (A) Severely compressed superior vena cava before treatment (arrow). (B) Cava angiographies showing (left side) occlusion of the superior vena cava and collateral flow through an alternative vessel (blue arrows). Catheter has passed through the occluded lumen of the superior vena cava (orange arrows). On the right side: after deployment of a stent which has reestablished the flow from the head and upper body to the right side of the heart.

None of the deaths could be ascribed to complications of the procedure or to SVC syndrome. SVC stenting is a well-established palliative treatment for malignant SVC syndrome. It is a simple, fast and safe procedure with good effect on the distressing complications of malignant mediastinal disease. Severe and potential fatal complications of percutaneous stenting of SVC are few. We found the stents fast, easy and safe to deploy and easy to be seen during fluoroscopy. Stenting of SVC has become widely accepted as a palliative treatment for SVC syndrome.

associated with malignant disease. Initial clinical experience with a new stent type has shown that it is safe, easy to deploy and with good clinical outcome relieving the patients from severe symptoms.

Publication

[A new nitinol stent for use in superior vena cava syndrome. Initial clinical experience.](#)

Andersen PE, Midtgaard A, Brenøe AS, Elle B, Duvnjak S.

J Cardiovasc Surg (Torino). 2015 Dec