

Pulmonary hypertension and the right diagnosis

Systemic sclerosis, also called scleroderma, is an autoimmune disease which involves skin and internal organs. Autoimmune means that the immunological system goes crazy and decides to kill the healthy cells as if they were virus or bacteria. In systemic sclerosis there is a specific attack against the cells which cover the internal side of the blood vessels, called endothelial cells. The consequence of this endothelial cells destruction is a vessel reaction characterized by vasoconstriction and vessel wall thickening. The final result is a reduced blood perfusion and the organs react with an abnormal wound healing process. The name *scleroderma* derives from Greek for 'hard skin' and emphasizes the dermatological component of the disease; this term was used for the first time by the Italian doctor Carlo Curzio in 1751. One of the most dreaded complications of this disease is *pulmonary hypertension*, which represents one of the main causes of death. Pulmonary hypertension means that there is a rise in pressure in the pulmonary artery, the big vessel which carries blood to the lungs to be oxygenated. The normal value is under 21 mmHg (millimeters of mercury), but we consider pulmonary hypertension when the pressure values reach 25 mmHg.

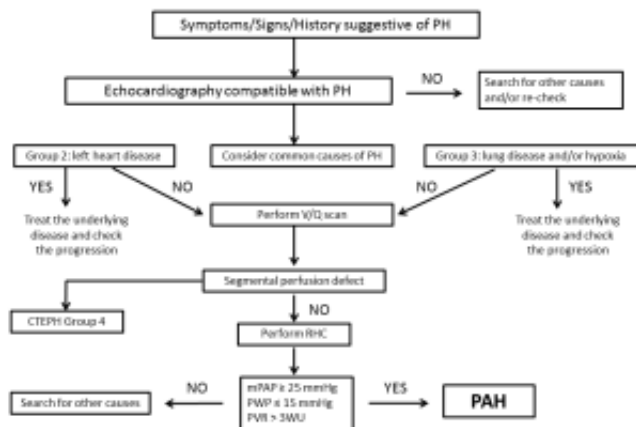


Fig.1 Diagnostic approach to pulmonary hypertension. PH: pulmonary hypertension; V/Q: ventilation/perfusion; RHC: right heart catheter; mPAP: mean pulmonary artery pressure; PWP: pulmonary wedge pressure; PVR: pulmonary vascular resistance; WU: wood units.

The consequence of pulmonary hypertension is a progressive and irreversible heart failure originating from the right ventricle, which is deformed and loses its ability to pump blood to the lungs. As we said before, systemic sclerosis is a multi-organ disease, so it is possible to identify three causes of pulmonary hypertension: left heart dysfunction, respiratory dysfunction and *pulmonary arterial hypertension (PAH)*. The first case is a consequence of a heart attack or is combined with an impaired functioning of the heart valves: instead of being pushed into the

systemic circulation, the blood goes back to the lungs, overloading vessels and increasing pulmonary pressure. The second case is a consequence of respiratory failure: when there are problems in gas exchange, the vessels localized at the base of the lungs reduce their diameter under a vasoconstriction stimuli. The blood moves from the base to the top of the lungs because this area is closer to the respiratory pathway, as a sort of physiological adaptation, but the consequence is pulmonary hypertension. The third case, called pulmonary arterial hypertension, is a specific remodeling process involving the little pulmonary arteries which carry blood within the lungs to be oxygenated. In this case the endothelial damage described before induces an excessive production of Endothelin-1, a protein able to induce vasoconstriction and vascular remodeling. This protein induces the cells of the vessel wall to replicate without control and the result is that the blood does not reach the lungs. So there is no oxygenation, leading to an irreversible heart failure within a few months. While in the first two cases the evolution of heart damage is relatively slow, in pulmonary arterial hypertension the average life expectancy without specific therapy is less than one year. Regarding diagnosis, there are no specific markers able to identify PAH so the diagnosis arrives after exclusion of other forms of pulmonary hypertension (Fig.1). As far as therapy is concerned, pulmonary hypertension secondary to left heart disease and pulmonary disease improves by treating the originating pathological process, while there are specific therapies only for PAH acting on the vessels. Before 2014 the aim of the treatment was to manage symptoms but recently a new drug able to improve prognosis has been approved. The knowledge of pulmonary hypertension and the right diagnosis are crucial to assess the most appropriate therapeutic strategy.

Publication

[Pulmonary hypertension: a correct diagnosis for a suitable therapy in scleroderma patients.](#)

Giordano N, Montella A, Corallo C, Ruocco G, Chirico C, Palazzuoli A, Nuti R, Pecetti G
Clin Exp Rheumatol. 2015 Jul-Aug;33 Suppl 91(4)