

## The amount of impaction and loss of reduction in osteoporotic proximal humeral fractures after surgery

More than 90% of proximal humerus fractures affect the elderly. Thus, we should understand that these are osteoporotic fractures. We can imagine the proximal humerus of the elderly as an egg shell, a broken egg shell. Fixation of such empty bone cannot be represented by a rigid plate with multiple rigid screw, as for regular bones.

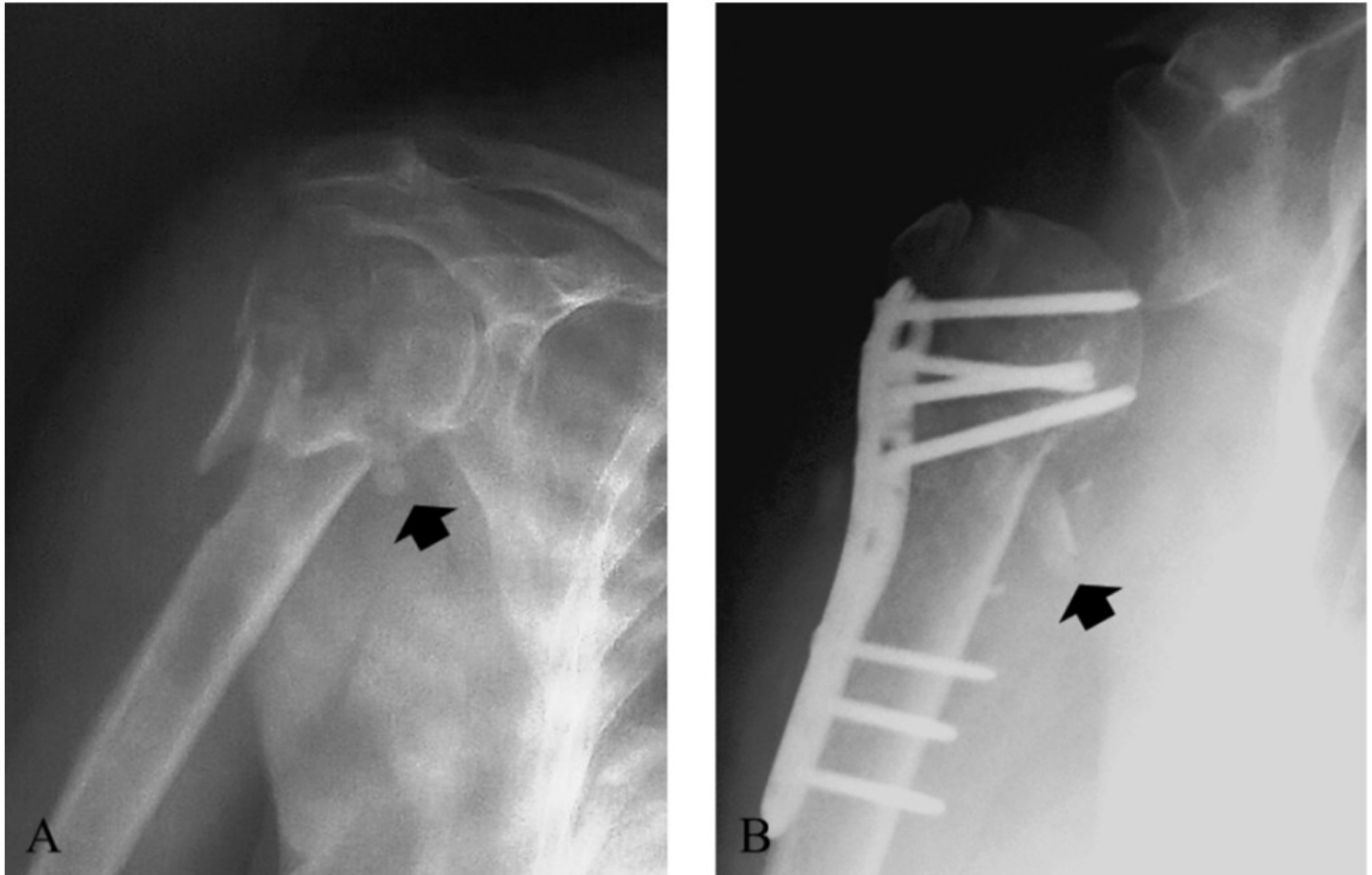


Fig. 1. A 77 years-old woman affected by an osteoporotic proximal humerus fracture. Two head screws show perforation of the articular surface at three months after surgical fixation. (Plate fixation)

Nevertheless, the most used fixation system is plating, because most of surgeons believe that they can control the reduction and impaction of the proximal humerus with multiple head screws that reach the subchondral bone. As described in this article, a relevant impaction and loss of reduction is often observed after plating of osteoporotic proximal humerus fractures, with an important effect

on clinical outcomes.

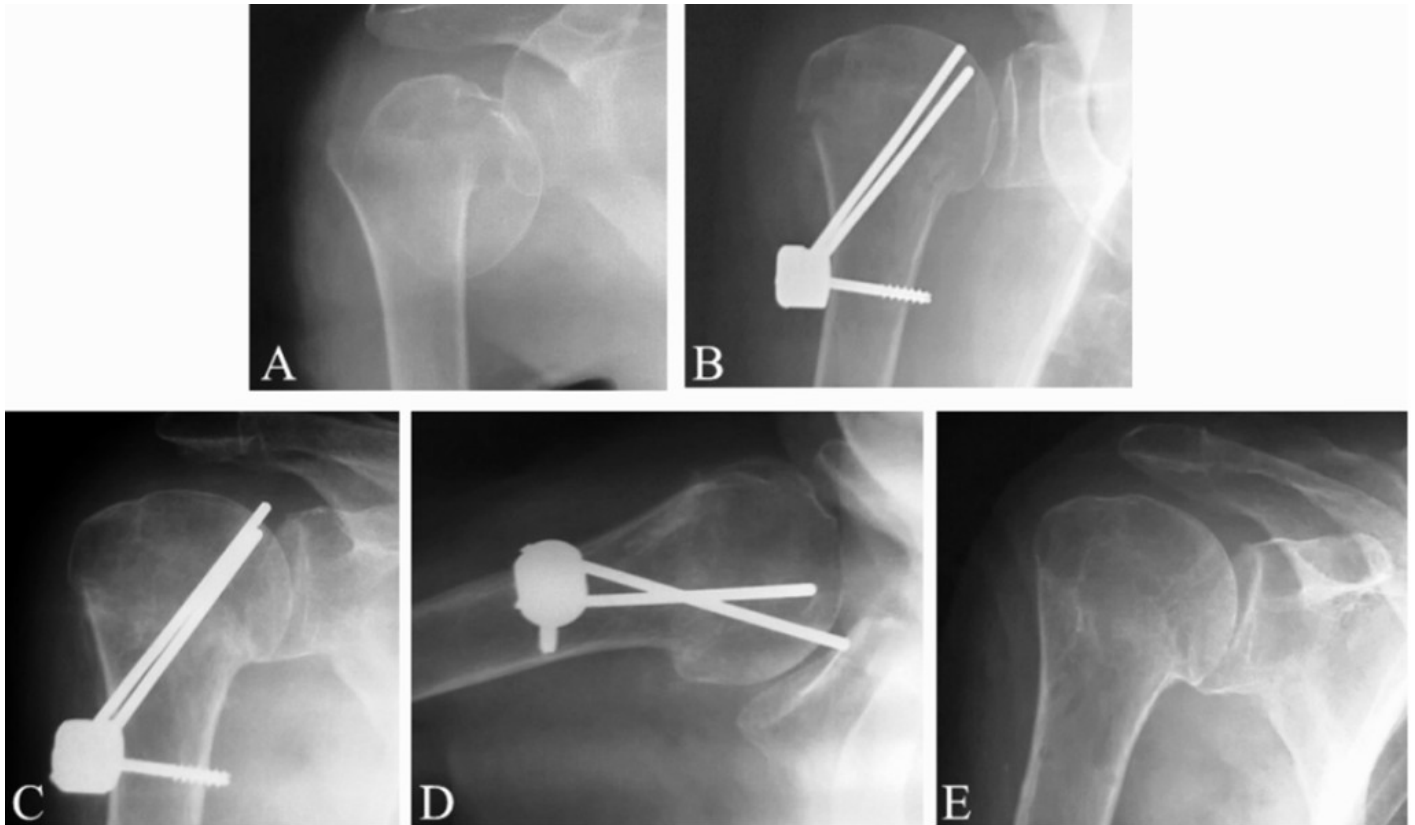


Fig. 2. A 88-year-old affected by an osteoporotic proximal humerus fracture showing severe impaction, with perforation of the humeral head, without significant loss of reduction. (Humerusblock fixation)

On the other side, a less rigid implant as the Humerusblock, a minimally invasive device designed for proximal humerus, shows higher amount of impaction but less loss of reduction, because of its particular design. Where is the best solution for these fragility fracture? The answer is still far away to be found, and surgeons in the world will continue to treat these osteoporotic fractures depending on their own preferences and personal experience, without clear evidence based medicine.

## Publication

[The amount of impaction and loss of reduction in osteoporotic proximal humeral fractures after surgical fixation.](#)

Carbone S, Papalia M

*Osteoporos Int. 2015 Sep 1*