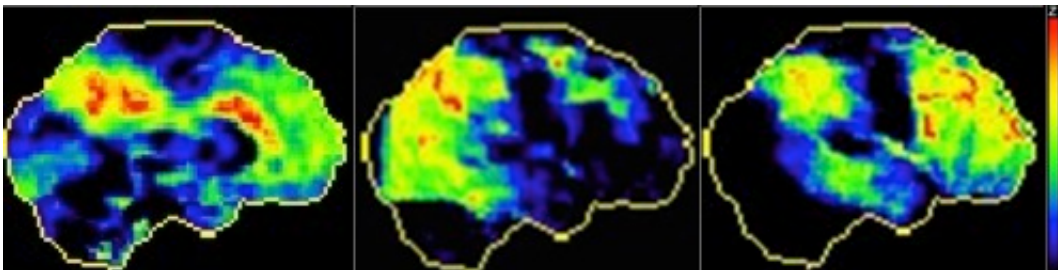


## The multiple faces of Alzheimer's disease: it's not only memory

When we think of Alzheimer's, the first thing that comes to our mind is memory loss. Memory problems were, until recently, a core and mandatory criteria to diagnose Alzheimer's disease. The word has spread through awareness programs and it became of common knowledge that "Alzheimer's disease = memory problems".

However, in the last decades, clinicians and scientists have come to recognize that Alzheimer's disease can also present with language, visuospatial or behavioural problems. In fact, it is now thought that as much as 25% of patients with Alzheimer's do not have memory problems in the early stages of the disease. These patients have the same pathogenic protein accumulations in their brains (amyloid plaques and tau tangles), yet when they initially complain to their clinicians of problems finding the right word, getting lost in common places or changes in their personality, and not of memory problems. Patients with such an 'atypical' presentation are often younger patients – typically in their fifties or sixties – and tend to have a more aggressive form of the disease.

When analysing these patients' brains at autopsy, researchers have found that, yet the faulty proteins are the same that in 'typical' Alzheimer's disease, they seem to target completely different brain regions. For example, the hippocampus, an important structure for the encoding of new memories, is prominently atrophied in typical Alzheimer's, yet often reserved in young-onset atypical cases; and patients initially presenting with language impairments seem to harbor more pathology and atrophy on the left side of their brain, the hemisphere responsible for language. Technologies such as positron emission tomography (PET) – a nuclear imaging technique allowing to measure the activity (or inactivity) of different brain regions in a living brain – have helped corroborating this finding. Indeed, we can see on the figure that patients with Alzheimer's disease can have completely different patterns of brain activity at PET.



The figure shows the positron emission tomography (PET) scan of three patients with different forms of Alzheimer's disease. Regions in yellow and red represent the most inactive (damaged) regions. At the left, we see the PET scan of a 84 years old patient with insidious memory problems (typical presentation). In the middle, we see the PET scan of a 57 year-old patient with progressive visuospatial problems; we can see the damage extending to posterior brain regions, notably the occipital cortex, responsible for the interpretation of visual inputs. At the right, we see the PET scan

of a 51 year-old patients with progressive personality changes, dishinhibition, and inappropriate behaviour; we can see the damage extending to frontal regions, subserving personality, judgment and complex thinking.

It is unknown why some proteins would target different brain regions. Interestingly, some studies have shown that these patients, despite harbouring different patterns of brain damage, all share a common feature: damage to the posterior cingulate cortex. This structure is a very important component of the brain's wiring system; it is at crossroads of most networks of neurons in the brain, such as the language network, memory network, attentional network, etc. Its centrality in the brain's architecture also makes this region more vulnerable to 'bad Alzheimer's proteins' deposition. We therefore believe that Alzheimer's pathology may start in this key brain region, then, from there, spread to other brain networks through neuronal connections. If it spreads through the language network, it causes languages problems; and if it spreads through the memory networks, it causes memory problems. But then, what determines in which networks it spreads? Mere randomness? Intriguingly, patients with the language variant of Alzheimer's disease often report having had language problems at schools and during their earlier life. Careful analysis indeed shows increased prevalence of childhood dyslexia in these patients compared to those with the typical presentation of Alzheimer's disease. In our article, we suggest that Alzheimer's pathology may spread through more vulnerable networks in brain architecture. We discuss how a better understanding of brain connections, though promising projects such as the Human Brain Project and the American B.R.A.I.N project (both funded at more than a billion dollars) will facilitate our understanding of the complex disease that Alzheimer's is. We believe that this new field of 'connectivity' research holds great promise to better understand, diagnose and treat Alzheimer variants in the future.

**David Bergeron**

*Clinique Interdisciplinaire de Mémoire (CIME), CHU de Québec,  
Québec, Canada.*

## **Publication**

[Untangling Alzheimer's disease clinicoanatomical heterogeneity through selective network vulnerability - an effort to understand a complex disease.](#)

Bergeron D, Bensaidane R, Laforce R Jr  
*Curr Alzheimer Res.* 2015 Nov 16