

The real life of crab louse

Pubic louse, also known as “crab” louse due to its form, is smaller than the head louse. It can lead to an infestation of the pubis (generally sexually transmitted), and sometimes of the eyelashes, or the body hair with severe itch. As its size is less than 2 mm, it is not easy to see these black dots between the hair.

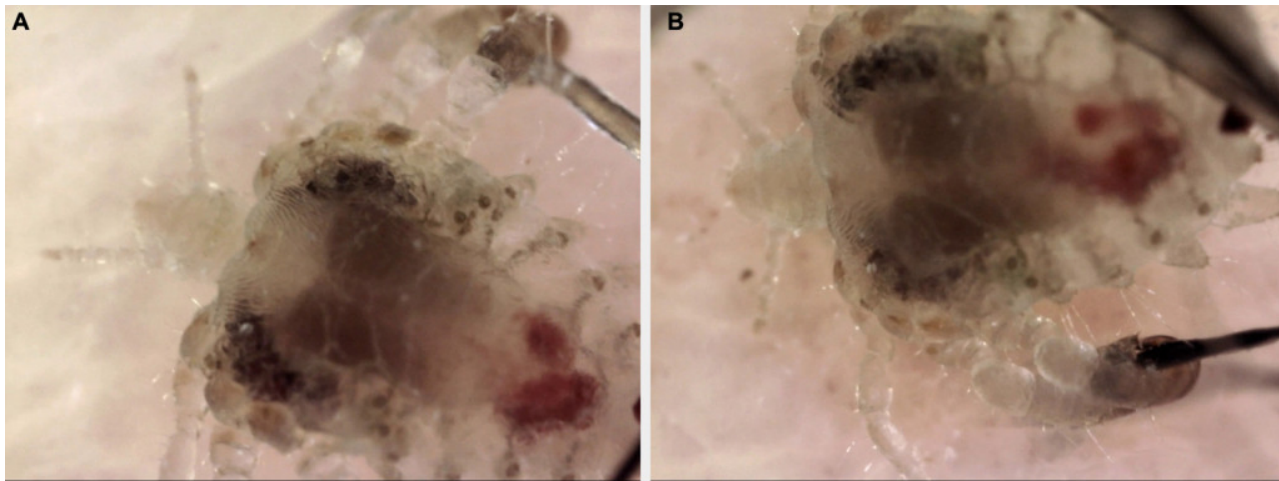


Fig. 1. A. Pubic louse. B. Pubic louse grasping hair.

New medical devices, as dermoscopy (epiluminescence microscopy, 5 megapixels, magnification 250 x), permits to watch the louse (*pictures*) , including its inner body; its characteristics are: smaller than the head and body lice, round form, thick back pair of legs and large claws, grasping 2 hairs (one from each side of its body). Contrarily, head louse catch generally 1 hair.

This so named “crab” louse, is closely related to the gorilla’s louse we could caught more than 3 million years ago, probably using the animal sleeping’s sites. Both belong to the same genus, *phtirius* (*phtirus pubis* and *phtirus gorilla*), when head and body lice are designated as *pediculus* (*pediculus capitis* and *pediculus corporis*).

But the “crab-gorilla” louse colonization is perhaps not achieved. Indeed, the popularity of pubic hair removal could put this louse endangered. For this reason, it has no choice, disappear or evolve, changing its usual home (the pubis), and colonizing other parts of the body, as the head.

François Desruelles

Private office, 20 avenue Malaussena, Nice, France
Archet 2 hospital, Nice, France

Publication

[A lousy diagnosis.](#)

Desruelles F.

N Engl J Med. 2015 Dec