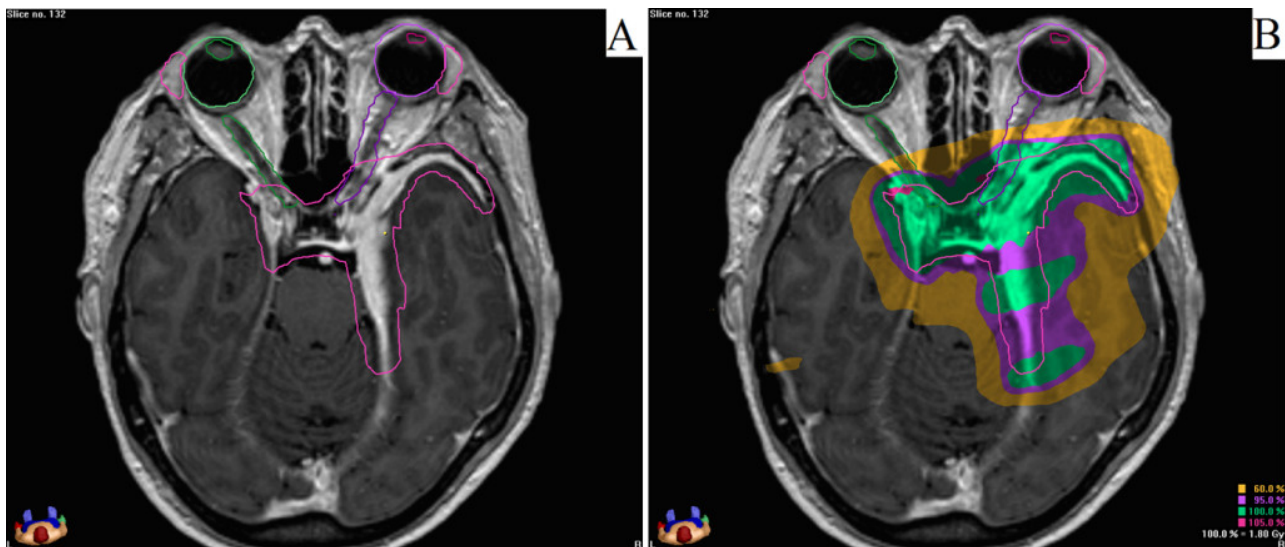


Visual side-effects in radiation treatment of meningioma

Meningioma is one of the most prevalent tumors in the brain. This kind of tumor arises from the natural layers covering the brain; so it is expected to see this tumor in different locations of brain. There are two main treatment modalities: surgical resection and radiotherapy. In many cases, neither total resection of the tumor nor any kind of surgical intervention is feasible due to its critical location, such as proximity to optic pathway. The role of radiotherapy is quite important, especially in these cases.

Generally, radiation should be applied precisely to the region of the tumor. At the same time we should try our best to spare the normal tissues surrounding the tumor in order to avoid adverse effects of radiation on normal parts of the brain. This point is really important when the tumor is located close to the optic structures – that are responsible for processing of visual function. Any of these structures has a tolerance dose of radiation. The more the radiation dose applied to a structure, the higher probability of its dysfunction; especially when this dose exceeds its tolerance dose. Of course other risk factors have been taken into consideration; they might have synergistic effect to radiation. That is the reason that sometimes adverse effects of radiation are observed when low doses of radiation are delivered to the relevant structure. In terms of visual side-effects of radiotherapy, patients' age, arterial hypertension, hypercholesterolemia, diabetes mellitus and smoking are the probable predisposing factors.



One of the cases with RION. A: MRI at the time of radiotherapy, showing the tumor region and structures of optic pathway. B: Each colour shows an area which receives more or equal to a special percentage of the total prescribed radiation dose.

In this study we evaluated 213 patients with meningioma who were treated in radiation-oncology department of “Klinikum rechts der Isar” in Munich, Germany between 2000 and 2013. We mainly evaluated delivered radiation doses to: (1) Lachrymal glands – that are responsible for keeping the eye globes safe by secreting tear; (2) Lenses – that are responsible for the entrance and necessary modification of the light inside the eyes; and (3) Optic nerves and chiasm – that are responsible for transferring of nervous messages from the eyes to the brain.

The adverse effect of radiotherapy on lachrymal glands, lenses and optic nerves/chiasm are dry eye, cataract and radiation induced optic neuropathy (RION) respectively.

We observed 15 cases of dry eye (7% of patients). In almost all of them the delivered radiation dose was much lower than the tolerance dose of lachrymal glands; but age and also the rate of hypercholesterolemia and arterial hypertension were higher in these patients. We also observed 24 cases of cataract (11.2% of patients). Again, in almost all of these cases, the delivered dose was lower than the tolerance of lenses; but age and also the rate of hypercholesterolemia, arterial hypertension, diabetes mellitus and smoking were higher in these patients.

There were only 2 cases with RION in our study. The delivered dose to the optic nerves and chiasm in these cases were not higher than their tolerance dose. But none of them had any of the above-mentioned risk factors. The point in these cases was that the tumor directly involved or compressed optic nerves or chiasm. This can justify the vulnerability of these structures.

The low percentages of patients with radiation induced optic toxicities including RION, dry eye and cataract, show that current treatment techniques and doses are safe. However, delivered doses to the relevant structures in most of patients with optical side effects were less than their tolerance doses. Hence, the role of the risk factors and co-morbidities including age, arterial hypertension, hypercholesterolemia, diabetes and smoking in increasing the radiation induced side effects should be investigated in more comprehensive studies.

Mostafa Farzin

*Department of Radiation Oncology, Klinikum rechts der Isar, Technische Universität München,
Munich, Germany*

Publication

[Optic toxicity in radiation treatment of meningioma: a retrospective study in 213 patients.](#)

Farzin M, Molls M, Kampfer S, Astner S, Schneider R, Roth K, Dobrei M, Combs S, Straube C.
J Neurooncol. 2016 Feb 6