

When is the vascular healing complete after the drug eluting stent implantation?

Currently, drug eluting stent (DES) is one of the most important medical devices for percutaneous coronary intervention in patients with coronary artery disease. 1st generation DES decreased the frequency of restenosis compared to bare metal stent, but there is delayed endothelialization or vascular healing which is the cause of stent thrombosis. On the 1st generation DES, the struts without endothelial coverage are frequently observed at follow-up by optical coherence tomography (OCT) which is an intracoronary imaging modality with high resolution of approximately 10-20 μm . 2nd generation DES are more biocompatible than 1st generation DES. It improved the vascular healing and decreased inflammatory response compared with the 1st generation DES. Previous study showed that 2nd generation DES, everolimus-eluting stent (EES) had a higher rate of endothelial coverage than 1st generation DES evaluated by OCT.

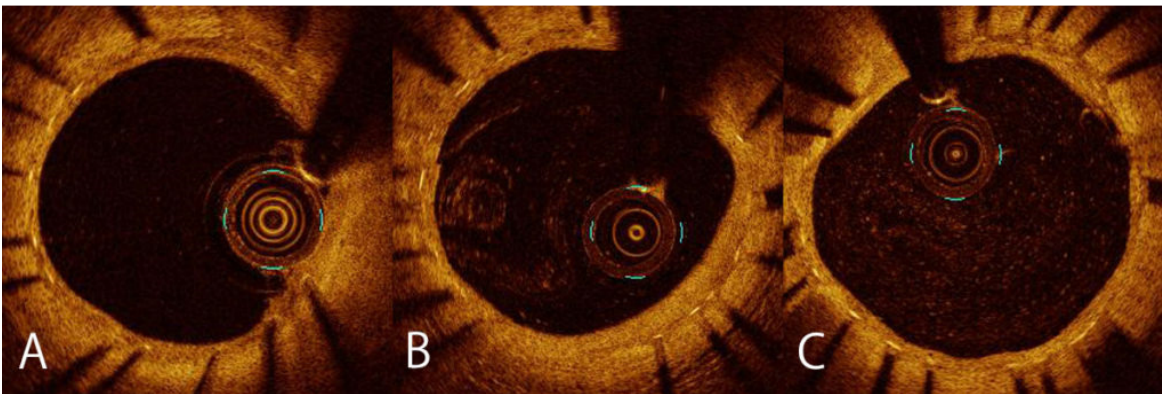


Fig. 1. OCT images of 6, 9 and 12 months follow-up
Optical coherence tomography images after everolimus-eluting stent implantation at 6 (A), 9 (B) and 12 (C) months follow-up. Stent struts were well-covered with neointima in all groups.

Because of vascular injury and platelet activation after stent implantation, the patients need dual antiplatelet therapy (DAPT) to decrease the risk of stent thrombosis. The patients usually receive standard DAPT for 12 months followed by aspirin monotherapy. However, complication of bleeding related to DAPT is a concern especially in patients at high risk of bleeding; shorter duration of DAPT may lead to less complication in those patients.

Recent study showed there was no difference in the frequency of cardiac event between patients with the short-term (3-6 months) DAPT and those with long-term (12 months) DES. To support these data, we need the OCT data which answer the question: “When is the vascular healing almost complete in 2nd generation DES?” The aim of our study was to evaluate the overtime vascular healing process after EES implantation at 6, 9 and 12 months by OCT.

In our study, we randomized the patients who underwent the PCI with EES into 3 groups according to the time of OCT follow-up: 6, 9 or 12 months. We analyzed the OCT image at every 1 mm and assessed the

uncovered struts. Frequency of uncovered strut was very small (0.9% at 6 months, 0.6% at 9 months, and 0.3% at 12 months) and there was no statically significant difference in the ratio of uncovered to total struts per section (RUTSS) >30% which is strongly associated with late stent thrombosis, between the 6-, 9-, 12 month groups (0.3% at 6 months, 0.3% at 9 months, and 0% at 12 months).

In this study, 2nd generation EES showed excellent vascular healing in 6 month follow-up. According to the result of no difference between the uncovered struts in 6, 9 and 12 months, it is indicated that the vascular healing of the stent were almost completed in 6 month.

In the current ACC guideline, short-term DAPT (6 months) is recommended to the patient with stable ischemic heart disease treated with DES implantation who has high risk of bleeding. Our findings could support the safety of short-term DAPT.

Kohki Ishida, Salvatore Brugaletta
*Cardiology Department, Cardiovascular Institute, Hospital Clinic,
Institut d'Investigacions Biomèdiques August Pi i Sunyer (IDIBAPS),
University of Barcelona, Barcelona, Spain*

Publication

[Overtime evaluation of the vascular HEALing process after everolimus-eluting stent implantation by optical coherence tomography. The HEAL-EES study.](#)

Otsuki S, Brugaletta S, Sabaté M, Shiratori Y, Gomez-Monterrosas O, Scalone G, Romero-Villafañe S, Hernández-Enríquez M, Freixa X, Martín-Yuste V, Masotti M

Cardiovasc Revasc Med. 2016 Jun